

ACCEPTED: April 2024

PUBLISHED ONLINE: May 2024

Schon JM, Gureck AE, Rhim HC, Malik GR, Tenforde AS. Treatment of chronic hallux sesamoid injuries with focused extracorporeal shockwave and physical therapy in an athletic population: a retrospective case series. *Dtsch Z Sportmed*. 2024; 75: 142-148. doi:10.5960/dzsm.2024.600

# Treatment of Chronic Hallux Sesamoid Injuries with Focused Extracorporeal Shockwave and Physical Therapy in an Athletic Population: A Retrospective Case Series

*Behandlung chronischer Hallux-Sesamoid-Verletzungen mit fokussierter extrakorporaler Stoßwelle und physikalischer Therapie bei einer Sportlerpopulation: Eine retrospektive Fallstudie*

## Summary

- ▶ **Problem:** Hallux sesamoid injuries can be a debilitating source of pain for patients. The mainstay of treatment is offloading to reduce symptoms, activity modification, injections, and other non-operative measures. When non-operative treatment fails, surgical resection is considered. This report describes a novel non-surgical treatment of chronic sesamoid injuries using focused extracorporeal shockwave therapy (F-SWT) combined with physical therapy (PT).
- ▶ **Methods:** Patients in this case series were identified through review of all cases during years 2018 to 2022 identified with hallux sesamoid mediated pain refractory to non-surgical management treated with F-SWT and foot intrinsic strengthening. Functional outcomes were compared at pretreatment and posttreatment using the foot and ankle ability measure (FAAM).
- ▶ **Results:** FAAM-ADL subscale scores improved pretreatment (median 63, IQR 53 to 74) to posttreatment (median 80.5, IQR 62.5 to 83),  $p = 0.0157$ . Similarly, FAAM-Sport subscale scores also increased pretreatment (median 13, IQR 5.25 to 14.75) to posttreatment (median 23, IQR 18.25 to 26),  $p = 0.0009$ . Eight of 11 (73%) patients met the minimally clinically important difference in FAAM-ADL or FAAM-Sport subscales.
- ▶ **Discussion:** This case series describes the use of F-SWT combined with foot intrinsic strengthening PT as a reasonable treatment strategy in athletes with hallux sesamoid injuries. Future prospective studies with long term outcomes are needed to compare the effectiveness of F-SWT and PT and clarify the optimal treatment protocol.

## KEY WORDS:

Sesamoiditis, Hallux Disorders, Bone Stress Injury, Intrinsic Foot Strengthening

## Introduction

The hallux sesamoids are round shaped bones planar to the first metatarsophalangeal (MTP) joint that distribute weight bearing forces onto the first ray and act as a fulcrum to increase the leverage and strength of the flexor hallucis brevis tendon (12). During ambulation, they provide stability and proper alignment of the first MTP joint as the toe pushes off the ground, facilitating the windlass mechanism to maintain arch stability during gait (26). The sesamoid complex supports up to 50% of body weight during normal gait and more than 300% when pushing off in athletic activity (27, 29). High stress on the hallux sesamoids can lead to injury, which can be debilitating and detrimental to the performance of running and jumping athletes.

Chronic hallux sesamoid pain may result from varied pathological conditions including sesamoiditis, bone stress injury, fracture non-union, symptomatic bipartite sesamoids, avascular necrosis

(or osteonecrosis), and advanced degeneration (23). Sesamoiditis is a clinical diagnosis which broadly refers to pain of either or both (medial and lateral) sesamoids, often associated with overuse or repetitive trauma and without evidence of acute fracture on plain radiographs. Chronic sesamoiditis if left untreated may lead to scarring of the tendons, ligaments and capsule of the sesamoid complex, which may limit motion of the sesamoids leading to further pain and loss of range of motion (26).

Initial management of sesamoid injuries is non-surgical with rest, ice, compression, elevation, over-the-counter pain medications and activity modification (8). Splinting, foot orthotics, sesamoid pads and footwear modifications can additionally reduce hallux dorsiflexion and off-load the sesamoids (4, 6). Physical therapy (PT), taping, first MTP joint mobilization, and strengthening of the flexor hallucis muscles can help improve forefoot and sesamoid



Scan QR Code and read article online.

## CORRESPONDING ADDRESS:

Adam S Tenforde, MD, Associate Professor  
Harvard Medical School, Department of  
Physical Medicine and Rehabilitation  
Spaulding Rehabilitation Hospital  
300 First Street, Charlestown, MA 02129, USA  
✉: atenforde@mgh.harvard.edu

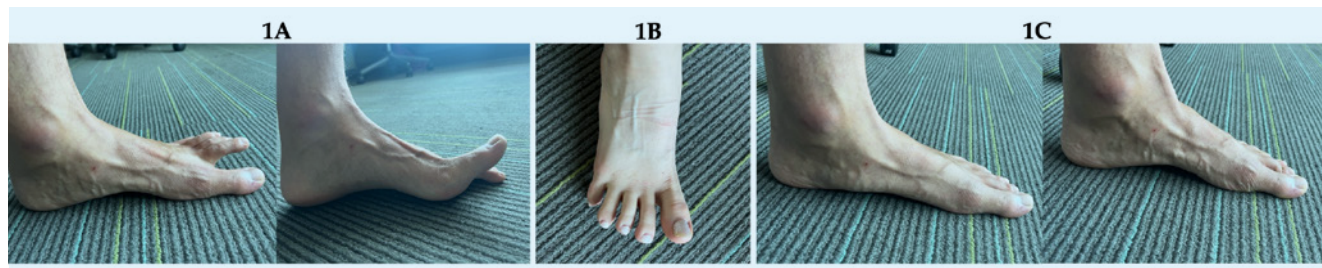


Figure 1

Demonstrations of key foot intrinsic plantar muscle strengthening exercises in the physical therapy program including toe yoga (1A), toe spreads (1B), and foot doming (1C).

position, mobility, and function (6, 26). For sesamoid fractures, immobilization is often recommended. Cortisone infiltration is not typically recommended for sesamoid injuries but can be reserved for symptomatic relief in chronic cases (15, 29).

Non-surgical management of sesamoid injuries has demonstrated good clinical results with respect to return to activity or sport (22, 30). Surgery can be considered for recalcitrant cases if non-operative management is unsuccessful. Isolated sesamoidectomy is the most common surgical intervention for sesamoid pain that has not responded to non-surgical treatment (22, 28). Surgical management has demonstrated good clinical outcomes and may lead to higher rates of return to play and prior activity level (9, 18, 22, 23, 24, 28).

Active individuals or athletes with chronic sesamoid injuries who are not improving with typical non-surgical treatment and do not wish to undergo surgical treatment remain challenging to treat. Extracorporeal shockwave therapy (ESWT) is an alternative non-operative treatment for many musculoskeletal conditions including tendinopathy, plantar fasciopathy, medial tibial stress syndrome and other bone conditions (19). There are two types of ESWT. Radial shockwave therapy (R-SWT) generates pressure waves while focused shockwave therapy (F-SWT) can generate a higher amplitude positive energy with more concentrated energy output. ESWT has been described in the treatment of many bone conditions including stress fractures, delayed union, non-union, osteonecrosis, and osteoarthritis and has shown promising results (1, 5, 7, 10, 17, 31).

The efficacy of F-SWT for chronic hallux sesamoid injuries is not well-described in the literature. Therefore, the purpose of this report was to describe outcomes of a novel non-surgical treatment of F-SWT combined with PT (progressive exercise therapy with supportive manual therapy) for management of chronic hallux sesamoid mediated pain.

## Materials and Methods

This case series describes patients identified using a retrospective chart review to identify individuals seen in a single sports medicine clinic from January 2018 to December 2022 with hallux sesamoid mediated pain who elected treatment with F-SWT and PT. The Mass General Brigham Institutional Review Board approved the study (Approval ID: 2022P003141). Inclusion criteria were: 1) hallux sesamoid injury diagnosed clinically; and 2) 3 months of pain refractory to non-surgical management. Exclusion criteria included: 1) prior sesamoid surgery, acute fracture, infection, arthritis, or inflammatory arthritis; 2) non-sesamoid related primary foot and ankle diagnosis; and 3) incomplete or missing functional outcome data.

Imaging studies were reviewed for evidence of MTP joint arthritis, osteonecrosis, bone stress injury, stress fracture,

acute fracture, bipartite sesamoid anatomy, plantar plate injury, bursitis, tendon injury and plantar fasciitis. Bone stress injuries are suggested by the presence of bone marrow edema within one or both sesamoids. The clinical entity of sesamoiditis may be associated with reactive soft tissue changes around the sesamoid complex and otherwise equivocal findings on MRI.

The Foot and Ankle Ability Measure Activities of Daily Living (FAAM-ADL) and Sport (FAAM-Sport) subscales were collected pretreatment and posttreatment to assess functional outcomes. The FAAM has been validated for patients with functional impairments from a wide variety of musculoskeletal conditions of the foot and ankle (14). Each item on the FAAM is scored on a 5-point Likert scale. The FAAM-ADL (21 items) and FAAM-Sport (7 items) scores range from 0 to 84 and 0 to 32, respectively, with higher scores indicating less limitation. The Minimally Clinically Important Difference (MCID) of the FAAM ADL and Sport subscales for assessing foot pathology have been reported as an improvement of 8 and 9 points, respectively (14).

The F-SWT treatment was performed using a Storz Medical Duolith (Storz Medical, Tagerwil, Switzerland). The shockwave treatment protocol was adapted from current practice recommendations for treating soft tissue and bone injuries (10, 32). Number of sessions, energy flux density and shocks per session were determined based on clinical judgement and treatment response. Typically, patients with sesamoiditis receive a minimum of 3 F-SWT sessions performed weekly, using a minimum of 1000 shocks at an energy achieving at least 0.15 mJ applied over the hallux sesamoid complex using clinical focusing technique to target application to sites of maximal pain. Patients with evidence of bone stress injury typically receive a minimum of 1000 shocks titrated up to a minimum energy of 0.45 mJ. Clinical focusing was performed without local anesthesia and patients were instructed to refrain from anti-inflammatory medications during and after treatment as this may interfere with the healing response (32). Patients with sesamoiditis were allowed to continue activities as tolerated. Patients with evidence of bone stress injury, avascular necrosis or pain interfering with gait were instructed on specific activity restrictions. All patients were concurrently prescribed PT focusing on hallux MTP joint mobilization and intrinsic foot core muscle strengthening (16). Calcium and vitamin D supplementation was recommended.

The PT treatment recommended for patients in this study is based on the foot core paradigm which emphasizes intrinsic plantar foot muscle strengthening and stabilization of the first ray (16, 20). Toe yoga, toe spreading, and foot doming are the main exercises (figure 1) (16). Strengthening of the flexor hallucis brevis is achieved with toe yoga. Toe yoga is performed by lifting the great toe while maintaining lesser toe contact with the ground (1A). This exercise is then reversed, maintain- ➤

Table 1

Demographic and descriptive clinical information. F=Female, M=Male, BMI=Body mass index, R=Right, L=Left, B/L=Bilateral, PT=Physical Therapy, CSI=Corticosteroid Injection, AVN=Avascular necrosis, BSI=Bone stress injury.

AGE (YEARS)	GENDER	BMI (KG/M <sup>2</sup> )	ACTIVITY	SYMPTOM DURATION (MONTHS)	SIDE	SESAMOID	DIAGNOSIS	PRIOR TREATMENT
54	F	20,9	Dance	24	R	Medial	Sesamoiditis + bipartite	Orthotics, PT, CSI, weight loss
38	F	30,7	Running	48	R	Medial	Sesamoiditis + Chronic AVN	Walking boot, dancer's pad, PT
33	M	22,4	Running, snow-boarding, tennis	56	R	Medial > lateral	Sesamoiditis	Rigid shoe
41	F	19,6	Running	18	R	Not specified	Sesamoiditis	Dancer's pad, CSI
20	F	22,4	Running	12	B/L	Medial	R: Sesamoiditis + BSI L: Sesamoiditis + BSI	Walking boot, orthotics, PT, bone stimulator
30	F	21,3	Running, Cycling	20	B/L	Medial	L: Sesamoiditis + bipartite R: Sesamoiditis + bipartite	Walking boot, dancer's pad, CSI, PT
52	F	23,6	Running	11	L	Medial	Sesamoiditis	Orthotics, dancer's pad, PT, CSI
21	M	21,6	Running	14	B/L	Medial>lateral	R: Sesamoiditis + bipartite + BSI L: Sesamoiditis + BSI	Walking boot, orthotics, bone stimulator
16	M	19,8	Downhill skiing, running	17	R	Medial	Sesamoiditis + BSI	Dancer's pad, rigid shoe, orthotic
27	F	22,6	Running	60	L	Medial	Sesamoiditis + BSI	PT, orthotics
19	M	20,5	Running	3	L	Medial	Sesamoiditis + BSI	PT, orthotics, bone stimulator

ing ground contact with the great toe, and extending the lesser toes (1A). Toe spreads involve abduction of the toes, strengthening the abductor hallucis muscle (1B). The intrinsic plantar foot muscles of the medial longitudinal arch are strengthened by foot doming. Foot doming is performed by elevating the arch of the foot while maintaining great toe contact with the ground (1C). Heel raises are performed for calf strengthening. These exercises are initially performed in a seated position and gradually progressed to standing. Manual joint manipulation including axial distraction of the first MTP joint, sesamoid mobilization, dorsal and plantar glides are incorporated to further improve mobility.

Median and interquartile range from 25th to 75th percentile (IQR) were calculated to describe demographic and clinical characteristics. The Shapiro-Wilk test was performed to test the normality of FAAM subscale data and showed significant deviation from a normal distribution. Wilcoxon signed-rank tests were therefore used to compare FAAM subscale scores pretreatment and posttreatment. A two-sided p-value of less than 0.05 was considered statistically significant. Statistical analysis was performed using STATA Version 16 (StataCorp LLC, College Station, TX).

Results

Eleven patients with 14 cases of sesamoid injury (3 with bilateral symptoms) were included for analysis. The 11 patients were athletes who primarily identified as female (n=7, 63%), median age was 30 (IQR: 20.5 to 39.5) years and median BMI was 21.6

(IQR: 20.7 to 22.5) kg/m<sup>2</sup>. Ten out of 11 were runners, with four of them being marathoners, while one patient was a dancer. Of the 14 anatomical locations for treatment, over half involved the right foot (n=8, 57%) and 3 patients received bilateral treatment. Median symptom duration prior to treatment with F-SWT was 18.5 (IQR: 12.5 to 42) months.

All 11 patients (14 feet) had clinical findings consistent with hallux sesamoid mediated pain. In addition, on MRI evaluation, 3 patients (4 feet) had bipartite sesamoids, 5 patients (7 feet) had bone stress injuries, and 1 patient (1 foot) had chronic osteonecrosis. Demographic and descriptive clinical data are presented in table 1.

Median follow-up time was 11 (IQR: 4 to 29) weeks. Patients received on average 5.4±2.5 F-SWT treatments at median energy of 0.25 mJ (IQR: 0.25 to 0.25) for 2000 shocks (IQR: 1500 to 2500) (table 2). Six of 11 patients (8 feet) with bone stress injury or avascular necrosis were advised activity restriction during early treatment. Five of 11 patients (6 feet) were allowed to maintain weight bearing activities as tolerated during treatment. Five of 11 patients (5 feet) continued to wear foot orthotics throughout treatment. Extracorporeal shockwave characteristics and treatment are detailed in table 2.

Changes in FAAM-ADL were significant from median pretreatment score of 63 (IQR: 53 to 74) to 80.5 (IQR 62.5 to 83) posttreatment (p=0.0157). Changes in FAAM-Sport subscale scores were also significant from median pretreatment score of 13 (IQR: 5.25 to 14.75) to 23 (IQR:18.25 to 26) posttreatment, (p=0.0009). Eight of 11 (73%) patients and 10 of 14 treatment sites (71%) met the MCID in either FAAM-ADL or FAAM-Sport

Table 2

Focused extracorporeal shockwave treatment characteristics and activity restrictions. ESWT=extracorporeal shockwave therapy, mJ=millijoules, F=female, M=male, R=right, L=left.

PATIENT	SIDE	TYPE OF ESWT	# OF TREATMENTS	TOTAL # OF SHOCKS	MINIMUM ENERGY (MJ)	MAXIMUM ENERGY (MJ)	ACTIVITY RESTRICTION
54 F	R	Focused	4	2000	0,25	0,3	Continue orthotics
38 F	R	Focused	3	3000	0,25	0,3	Offload with crutches, no running
33 M	R	Focused	4	1500	0,25	0,25	None
41 F	R	Focused	6	1000	0,15	0,15	None
20 F	R	Focused	6	2500	0,35	0,55	Non-weight bearing with crutches
	L	Focused	6	2500	0,25	0,45	Protected weight bearing with pneumatic boot
30 F	R	Focused	4	1000	0,25	0,25	None
	L	Focused	4	1000	0,25	0,25	None
52 F	L	Focused	4	1500	0,25	0,25	Continue orthotics with dancer's pad
21 M	R	Focused	4	2000	0,2	0,5	No running
	L	Focused	4	2000	0,2	0,5	No running
16 M	R	Focused	5	2500	0,35	0,55	No running, custom orthotic
27 F	L	Focused	7	3000	0,35	0,55	No running, cushioned shoe for cycling, orthotics
19 M	L	Focused	12	2000	0,25	0,25	No running or cycling, custom orthotic

Table 3

Functional outcome data. F=Female, M=Male, R=Right, L=Left, FAAM=Foot and Ankle Ability Measure, ADL=Activities of Daily Living. \*=met Minimally Clinically Important Difference (MCID), which is defined as a difference of 8 in the FAAM-ADL score or a difference of 9 in the FAAM-Sport score. ^=Unable to achieve MCID due to pre-treatment scores > 76 in the FAAM-ADL score or > 23 in the FAAM-Sport score.

PATIENT	FAAM-ADL SCORE		FAAM-SPORT SCORE		FOLLOW-UP PERIOD (WEEKS)
	PRE-TREATMENT	POST-TREATMENT	PRE-TREATMENT	POST-TREATMENT	
54 F	56	70*	9	18*	4
38 F	52	61*	13	19	4
33 M	65	67	18	26	3
41 F	68	79*	14	30*	22
20 F	13(R) 13(L)	83(R)* 83(L)*	0(R) 0(L)	24(R)* 24(L)*	23
30 F	76(R) 76(L)	84(R)* 83(L)	4(R) 4(L)	20(R)* 22(L)*	35
52 F	35	41	15	9	5
21 M	61(R) 61(L)	52(R) 53(L)	13(R) 13(L)	15(R) 15(L)	3
16 M	78	83^	16	26*	11
27 F	80	83^	12	30*	46
19 M	66	82*	20	26	47

subscales; 5 of the 14 (36%) met MCID criteria for both subscales. The descriptive data and functional outcome measures are reported in table 3.

There were no reported adverse effects related to treatment. One patient (54 F) elected to receive medial hallux sesamoidectomy following treatment despite functional improvement. Another patient (21 M) had clinically significant decrease in FAAM-ADL despite clinical notes reported mild improvement in pain but pain with running.

### Discussion

The results of this study demonstrate that F-SWT combined with PT contributed to functional gains in an athletic population and may be an effective method to treat hallux sesamoid pain as both the FAAM ADL and the FAAM Sport improved

significantly. Perhaps even more notable was that over 70% of treatment sites demonstrated clinically relevant improvement in at least one of these scales, as measured by the MCID. F-SWT was well tolerated by all patients without adverse events.

Non-operative treatment of hallux sesamoid injuries has demonstrated similar return to activity rates compared to surgery, with the systematic review by Robertson et al noting 86% return to activity following non-operative treatment and 95% following surgery (22). Unfortunately, a high percentage of patients report persistent pain and 10 to 30% of patients eventually convert to hallux sesamoidectomy (22, 30). Patient reported outcomes following hallux sesamoidectomy have demonstrated high patient satisfaction and return to pre-injury level of athletic activity (2, 23, 28).

Despite evidence in the literature suggesting better outcomes with surgery, some athletic individuals choose to



exhaust non-operative alternatives and are hesitant to consider surgical options to avoid risks and extended recovery associated with surgery. Feared surgical complications include infection, development of hallux valgus or varus deformity, loss of range of motion, disruption of the windlass mechanism, and great toe flexor weakness, which may alter biomechanics of push-off and gait (3, 9, 18, 28). One of the main advantages of ESWT treatment in athletes is that they can often participate in training or competition if pain is tolerated and has a minimal risk profile (21). Physical therapy foot core exercises are implemented with ESWT to strengthen intrinsic plantar foot muscles important to gait mechanics and functional stability of the foot (11, 16, 20).

Our results are comparable with the two prior reports investigating the use of R-SWT for hallux sesamoid disorders (25, 33). Saxena et al reported on 10 patients who received R-SWT and 90% of participants had partial or full relief of symptoms with average return to activity at 10 weeks (25). Notably, only 30% of subjects were able to continue with their activity during treatments without cessation due to limitations from symptoms (25). In the case report by Thompson et al, one patient with chronic sesamoid osteonecrosis underwent 8 sessions of R-SWT with resolution of symptoms at the end of treatment (33). He subsequently underwent a 12-week rehabilitation program and was able to return to sport. At 1 year follow up, his pain had not returned (33). Our study did not evaluate time to return to activity, but our study finding suggests that most patients improved as demonstrated by FAAM subscale scores. Roughly half (5 of 11) of the patients in our study were not restricted from athletic activities during treatment. This can be quite impactful during the sporting season, especially when there are not opportunities for an athlete to miss training or competitive sessions. The remaining half of patients (6 of 11) with bone stress injury or avascular necrosis were recommended activity restriction or offloading during initial treatment and high impact activities were gradually introduced in physical therapy.

A multitude of hallux sesamoid pathologies may be amenable to treatment with ESWT and foot core PT as demonstrated by the results of our study and the two previously mentioned studies. Both focused and radial ESWT have been well described in the treatment of soft-tissue pathology. F-SWT has been proposed as effective treatment for bone conditions such as stress fractures, nonunion fractures, and osteonecrosis. F-SWT allows for higher flux energy density proposed to promote osteogenesis, bone remodeling, periosteal bone formation, reduce inflammation, and neovascularization (13, 32, 34, 35, 36). Because ESWT targets multiple structures in the sesamoid complex including bone, ligaments, capsule and tendons, combining radial and focused ESWT may be most effective. However, this should be substantiated by future larger trials.

While this case series represents the first report describing outcomes using F-SWT and PT for hallux sesamoid injuries, there are several limitations in this study. First, we did not have a control group, and therefore, we could not measure the relative influence of F-SWT and PT compared with time alone. Nonetheless, given the long duration of symptoms (median 18.5 months), it would be less likely that time itself contributed to recovery in these patients. Second, because we treated the patients with F-SWT, foot core exercises, and manual therapy, we cannot fully account for relative influence of these treatments to outcomes observed. Third, we had a small sample size composed of an athletic population, and thus, the findings of this study may not be generalized to other populations. Lastly, because median follow-up was 11 (IQR: 4 to 29) weeks, we could

not confirm how long the effect of our treatment would last. Future randomized controlled trials with long term follow-up would be needed to clarify optimal treatment protocol using ESWT and PT for this condition. ■

#### Conflict of Interest

*The authors have no conflict of interest.*

#### Summary Box

Hallux sesamoid injuries are a source of foot pain that can limit those who are physically active due to pain and loss of function. The aim of this report is to describe outcomes in using focused shockwave therapy (F-SWT) combined with physical therapy to improve pain and function.

In a population of 11 athletes with 14 chronic hallux sesamoid injuries (symptoms >3 months) we observed that 8 of 11 athletes had measurable gains in function using the foot and ankle ability measure for sport and/or activities of daily living. While the study is limited by small cohort of athletes and study design, these results suggest F-SWT combined with physical therapy may be a reasonable treatment option for chronic hallux sesamoid injuries.

## References

- (1) An S, Li J, Xie W, Yin N, Li Y, Hu Y. Extracorporeal shockwave treatment in knee osteoarthritis: therapeutic effects and possible mechanism. *Biosci Rep*. 2020; 40: BSR20200926. doi:10.1042/BSR20200926
- (2) Anderson RB, Shawen SB. 21 - Great-Toe Disorders. In: Porter DA, Schon LC, eds. *Baxter's the Foot and Ankle in Sport* (Third Edition). Philadelphia: Elsevier. 2020: 390-410.
- (3) Aper RL, Saltzman CL, Brown TD. The effect of hallux sesamoid excision on the flexor hallucis longus moment arm. *Clin Orthop Relat Res*. 1996; April: 209-217. doi:10.1097/00003086-199604000-00025
- (4) Axe MJ, Ray RL. Orthotic treatment of sesamoid pain. *Am J Sports Med*. 1988; 16: 411-416. doi:10.1177/036354658801600419
- (5) Beling A, Saxena A, Hollander K, Tenforde AS. Outcomes Using Focused Shockwave for Treatment of Bone Stress Injury in Runners. *Bioengineering* (Basel). 2023; 10: 885. doi:10.3390/bioengineering10080885
- (6) Carroll LA, Paulseth S, Martin RL. Forefoot Injuries in Athletes: Integration of the Movement System. *Int J Sports Phys Ther*. 2022; 17: 81-89. doi:10.26603/001c.30021
- (7) Chen L, Ye L, Liu H, Yang P, Yang B. Extracorporeal Shock Wave Therapy for the Treatment of Osteoarthritis: A Systematic Review and Meta-Analysis. *BioMed Res Int*. 2020; 2020: 1907821. doi:10.1155/2020/1907821
- (8) Cohen BE. Hallux sesamoid disorders. *Foot Ankle Clin*. 2009; 14: 91-104. doi:10.1016/j.fcl.2008.11.003
- (9) Ford SE, Adair CR, Cohen BE, Davis WH, Ellington JK, Jones CP, Anderson RB. Efficacy, Outcomes, and Alignment Following Isolated Fibular Sesamoidectomy via a Plantar Approach. *Foot Ankle Int*. 2019; 40: 1375-1381. doi:10.1177/1071100719868734
- (10) Furia JP, Rompe JD, Cacchio A, Maffulli N. Shock wave therapy as a treatment of nonunions, avascular necrosis, and delayed healing of stress fractures. *Foot Ankle Clin*. 2010; 15: 651-662. doi:10.1016/j.fcl.2010.07.002
- (11) Gureck AE, Schon J, Rhim HC, Wasserman L, Hollander K, Tenforde A. Management of first metatarsophalangeal joint pain in runners with extracorporeal shockwave therapy and physical therapy. *Dtsch Z Sportmed*. 2023; 74: 33-39. doi:10.5960/dzsm.2023.557
- (12) Jahss MH. The sesamoids of the hallux. *Clin Orthop Relat Res*. 1981; 88-97. doi:10.1097/00003086-198106000-00016
- (13) Ma HZ, Zeng BF, Li XL. Upregulation of VEGF in subchondral bone of necrotic femoral heads in rabbits with use of extracorporeal shock waves. *Calcif Tissue Int*. 2007; 81: 124-131. doi:10.1007/s00223-007-9046-9
- (14) Martin RL, Irrgang JJ, Burdett RG, Conti SF, Van Swearingen JM. Evidence of validity for the Foot and Ankle Ability Measure (FAAM). *Foot Ankle Int*. 2005; 26: 968-983. doi:10.1177/107110070502601113
- (15) McCormick JJ, Anderson RB. The great toe: failed turf toe, chronic turf toe, and complicated sesamoid injuries. *Foot Ankle Clin*. 2009; 14: 135-150. doi:10.1016/j.fcl.2009.01.001
- (16) McKeon PO, Hertel J, Bramble D, Davis I. The foot core system: a new paradigm for understanding intrinsic foot muscle function. *Br J Sports Med*. 2015; 49: 290. doi:10.1136/bjsports-2013-092690
- (17) Moretti B, Notarnicola A, Moretti L, Patella S, Tatò I, Patella V. Bone healing induced by ESWT. *Clin Cases Miner Bone Metab*. 2009; 6: 155-158.
- (18) Pearson JM, Moraes LVM, Paul KD, Peng J, Chinnakkannu K, McKissack HM, Shah A. Is Fibular Sesamoidectomy a Viable Option for Sesamoiditis? A Retrospective Study. *Cureus*. 2019; 11: e4939. doi:10.7759/cureus.4939
- (19) Reilly JM, Bluman E, Tenforde AS. Effect of Shockwave Treatment for Management of Upper and Lower Extremity Musculoskeletal Conditions: A Narrative Review. *PM R*. 2018; 10: 1385-1403. doi:10.1016/j.pmrj.2018.05.007
- (20) Reilly T, Wasserman L, Tenforde AS. Non-Operative Management of Symptomatic Hallux Limitus: A Novel Approach of Foot Core Stabilization and Extracorporeal Shockwave Therapy. *Video Journal of Sports Medicine*. 2022; 2. doi:10.1177/26350254221089354
- (21) Rhim HC, Borg-Stein J, Sampson S, Tenforde AS. Utilizing Extracorporeal Shockwave Therapy for in-Season Athletes. *Healthcare* (Basel). 2023; 11: 1006. doi:10.3390/healthcare11071006
- (22) Robertson GAJ, Goffin JS, Wood AM. Return to sport following stress fractures of the great toe sesamoids: a systematic review. *Br Med Bull*. 2017; 122: 135-149. doi:10.1093/bmb/ldx010
- (23) Saxena A, Fournier M, Patel P, Maffulli N. Sesamoidectomy in Athletes: Outcomes From 2-Centers. *J Foot Ankle Surg*. 2022; 61: 139-142. doi:10.1053/j.jfas.2021.07.008
- (24) Saxena A, Krisdakumtorn T. Return to Activity after Sesamoidectomy in Athletically Active Individuals. *Foot Ankle Int*. 2003; 24: 415-419. doi:10.1177/107110070302400507
- (25) Saxena A, Yun A, Patel R, Gerdesmeyer L, Maffulli N. Radial Soundwave for Sesamoidopathy in Athletes: A Pilot Study. *J Foot Ankle Surg*. 2016; 55: 1333-1335. doi:10.1053/j.jfas.2016.07.024
- (26) Shamus J, Shamus E, Gugel RN, Brucker BS, Skaruppa C. The effect of sesamoid mobilization, flexor hallucis strengthening, and gait training on reducing pain and restoring function in individuals with hallux limitus: a clinical trial. *J Orthop Sports Phys Ther*. 2004; 34: 368-376. doi:10.2519/jospt.2004.34.7.368
- (27) Shereff MJ, Bejjani FJ, Kummer FJ. Kinematics of the first metatarsophalangeal joint. *J Bone Joint Surg Am*. 1986; 68: 392-398. doi:10.2106/00004623-198668030-00012
- (28) Shimozono Y, Hurley ET, Brown AJ, Kennedy JG. Sesamoidectomy for Hallux Sesamoid Disorders: A Systematic Review. *J Foot Ankle Surg*. 2018; 57: 1186-1190. doi:10.1053/j.jfas.2018.03.044
- (29) Sims AL, Kurup HV. Painful sesamoid of the great toe. *World J Orthop*. 2014; 5: 146-150. doi:10.5312/wjo.v5.i2.146
- (30) Stein CJ, Sugimoto D, Slick NR, Lanois CJ, Dahlberg BW, Zwicker RL, Micheli LJ. Hallux sesamoid fractures in young athletes. *Phys Sportsmed*. 2019; 47: 441-447. doi:10.1080/00913847.2019.1622246
- (31) Taki M, Iwata O, Shiono M, Kimura M, Takagishi K. Extracorporeal shock wave therapy for resistant stress fracture in athletes: a report of 5 cases. *Am J Sports Med*. 2007; 35: 1188-1192. doi:10.1177/0363546506297540
- (32) Tenforde AS, Borgstrom HE, DeLuca S, McCormack M, Singh M, Hoo JS, Yun PH. Best practices for extracorporeal shockwave therapy in musculoskeletal medicine: Clinical application and training consideration. *PM R*. 2022; 14: 611-619. doi:10.1002/pmrj.12790
- (33) Thompson D, Malliaropoulos N, Padhiar N. Sesamoid osteonecrosis treated with radial extracorporeal shock wave therapy. *BMJ Case Rep*. 2017; bcr2017219191. doi:10.1136/bcr-2017-219191
- (34) Wang CJ, Wang FS, Yang KD, Weng LH, Sun YC, Yang YJ. The effect of shock wave treatment at the tendon-bone interface-an histomorphological and biomechanical study in rabbits. *J Orthop Res*. 2005; 23: 274-280. doi:10.1016/j.jorthres.2004.07.004
- (35) Wang CJ, Yang KD, Wang FS, Hsu CC, Chen HH. Shock wave treatment shows dose-dependent enhancement of bone mass and bone strength after fracture of the femur. *Bone*. 2004; 34: 225-230. doi:10.1016/j.bone.2003.08.005
- (36) Wang FS, Yang KD, Chen RF, Wang CJ, Sheen-Chen SM. Extracorporeal shock wave promotes growth and differentiation of bone-marrow stromal cells towards osteoprogenitors associated with induction of TGF-beta1. *J Bone Joint Surg Br*. 2002; 84-B: 457-461. doi:10.1302/0301-620X.84B3.0840457